







## Micromarsupialization technique in oral ranula: report of two clinical cases in child patient

Lucas Fernando Oliveira Tomáz Ferrareso<sup>1</sup> , Fábio Anevan Ubiski Fagundes<sup>1</sup> ,  
Mayra Frasson Paiva<sup>2</sup> , Rodrigo Hayashi Sakuma<sup>2</sup> , Cássia Cilene Dezan Garbelini<sup>2</sup> ,  
Farli Aparecida Carrilho Boer<sup>2</sup> .

**Abstract: Introduction:** Oral ranulas are pseudocysts resulting from the retention of mucus or extravasation of saliva that often affect children. This article aims to report two clinical cases of oral ranulas and discuss the treatment using the micromarsupialization technique. **Case report 1:** 6-year-old girl, attended the Emergency Room of the Baby Clinic of the State University of Londrina complaining of a “ball under the tongue” lasting approximately 3 months. Clinically, reddish bubble of approximately 1.5 cm in diameter was noted located on the right side of the dome-shaped mouth floor, sessile base and fluctuating. **Case report 2:** 5-year-old girl, attended the same service with a complaint of “bubble on the tongue” lasting approximately 2 months. Clinically, pink-colored bubble similar to the mucosa of approximately 1 cm in diameter was observed located on the left side of the floor of the mouth with a circumscribed shape, sessile base and fluctuating. Based on the clinical aspects and the current history of the lesions, the diagnosis was oral ranula and the surgical treatment performed was micromarsupialization. In a clinical follow-up of 8 and 6 months, respectively, total regression of the lesions was observed, with no clinical signs of recurrence. **Conclusion:** Based on the reported clinical cases, it can be concluded that the use of micromarsupialization technique represents an effective surgical procedure in children due to its quick execution, conservative approach, without the use of local infiltrative anesthesia, well tolerated and with good prognosis.

**Key words:** Oral surgical procedures, pediatric dentistry, ranula, emergencies.

## Técnica de micromarsupialización en ránula oral: reporte de dos casos clínicos en pacientes infantiles

**Resumen: Introducción:** Ránulas orales son pseudoquistes resultantes de la retención de mucus o extravasación de saliva que suelen afectar a los niños. Este artículo tiene como objetivo reportar dos casos clínicos de ránulas orales y discutir el tratamiento mediante la técnica de micromarsupialización. **Reporte de caso 1:** Niña de 6 años de edad, acudió al servicio de urgencia en odontopediatría de la Bebé Clínica de la Universidad Estatal de Londrina refiriendo “bolita debajo de la lengua” de aproximadamente 3 meses de evolución. Clínicamente se observó burbuja rojiza de aproximadamente 1,5 cm de diámetro ubicada en el lado derecho del suelo bucal en forma de cúpula, base sésil y fluctuante. **Reporte de caso 2:** Niña de 5 años, acudió al mismo servicio con queja de “burbuja en la lengua” de aproximadamente 2 meses de evolución. Clínicamente se observó burbuja de color rosado similar a la mucosa de aproximadamente 1 cm de diámetro ubicada en el lado izquierdo del suelo bucal con forma circunscrita, base sésil y fluctuante. Con base en los aspectos clínicos y la historia actual de las lesiones, el diagnóstico fue ránula oral y el tratamiento quirúrgico realizado fue micromarsupialización. En el seguimiento clínico de 8 y 6 meses, respectivamente, hubo regresión total de las lesiones sin signos clínicos de recurrencia. **Conclusión:** Con base en dos casos clínicos reportados, se puede concluir que el uso de la técnica de micromarsupialización representa procedimiento quirúrgico efectivo en niños por su rápida ejecución, abordaje conservador, sin el uso de anestesia local infiltrativa, bien tolerado y con buen pronóstico.

**Palabras clave:** Odontología Pediátrica, procedimientos quirúrgicos orales, ránula, urgencias.

<sup>1</sup> Pediatric Dentistry Student, Department of Oral Medicine and Dentistry for Children, State University of Londrina, Londrina, PR, Brazil.

<sup>2</sup> Associate Professor, Department of Oral Medicine and Dentistry for Children, State University of Londrina, Londrina,

## Técnica de micromarsupialização em rânula oral: relato de dois casos clínicos em paciente infantil

**Resumo: Introdução:** Rânulas orais são pseudocistos resultantes da retenção de muco ou extravasamento de saliva que frequentemente acometem crianças. Este artigo objetiva relatar dois casos clínicos de rânulas orais e discutir o tratamento utilizando a técnica de micromarsupialização. **Relato de caso 1:** menina de 6 anos, compareceu ao Pronto-Socorro da Bebê Clínica da Universidade Estadual de Londrina queixando-se de “bola embaixo da língua” com duração aproximada de 3 meses. Ao exame intraoral, notou-se bolha avermelhada de aproximadamente 1,5 cm de diâmetro localizada no lado direito do assoalho bucal em forma de cúpula, base sésil e flutuante. **Relato de caso 2:** menina de 5 anos, compareceu ao mesmo serviço com queixa de “bolha na língua” com duração aproximada de 2 meses. Clinicamente, notou-se bolha de coloração rósea igual à mucosa de aproximadamente 1 cm de diâmetro localizada no lado esquerdo do assoalho bucal de formato circunscrito, base sésil e flutuante. Com base nos aspectos clínicos e na história atual das lesões, o diagnóstico foi de rânula oral e o tratamento cirúrgico realizado foi a micromarsupialização. Em acompanhamento clínico de 8 e 6 meses, respectivamente, foi observado regressão total das lesões sem sinais clínicos de recidiva. **Conclusão:** A partir dos casos clínicos relatados, pode-se concluir que a utilização da técnica de micromarsupialização representa um procedimento cirúrgico eficaz em crianças devido à rápida execução, abordagem conservadora, sem uso de anestesia local infiltrativa, bem tolerada e com bom prognóstico.

**Palavras-chave:** Odontopediatria, procedimentos cirúrgicos bucais, rânula, urgências.

### Introduction

Ranulas are pseudocysts resulting from mucus retention or extravasation of saliva. It develops as a result of trauma and/or obstruction of the excretory duct of the major salivary gland.<sup>1-3</sup> This lesion can be classified into two types: oral ranulas (OR) which are confined to the floor of the mouth and plunging ranulas, which result from the collection of mucus along the fascial planes of the neck into the surrounding soft tissues.<sup>3,4</sup>

It is estimated in the general population the prevalence of 0.2 cases per 1,000 people<sup>5</sup> with a predilection for children and adolescents.<sup>3,6,7</sup> No racial or sexual predilection is associated with OR<sup>3</sup>, although some authors report a higher prevalence for females.<sup>8,9</sup> Clinically, OR appear as floating, dome-shaped, normochromic, translucent to

blue swellings, located in the midline of the floor of the mouth<sup>10</sup> or laterally, resembling a frog's belly.<sup>5,10</sup>

The treatment of OR remains controversial. These lesions tend to resolve spontaneously. However, if they are symptomatic, persistent, and are not self-resolving<sup>3</sup>, various methods are available for the treatment ranging from simple aspiration to complete or partial excision of the ranula and/or the sublingual salivary gland.<sup>11</sup> They include: surgical excision, sclerotherapy<sup>4,11</sup>, cryotherapy, laser ablation<sup>3,11</sup>, hydro-dissection<sup>11</sup>, marsupialization and micromarsupialization.<sup>3,4,11</sup>

This article aims to report two clinical cases of OR in a child patient, as well as to discuss the choice of the surgical technique of micromarsupialization as a treatment.

## Case Reports

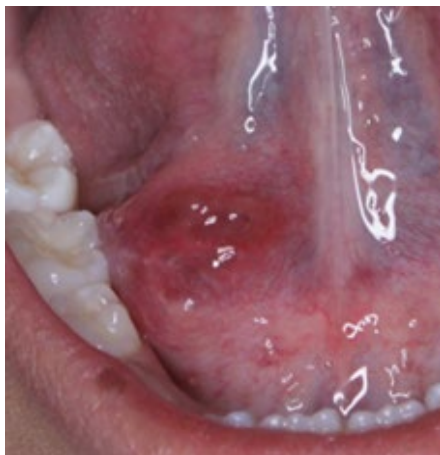### Case 1

A 6-year-old girl, melanoderma, attended the Pediatric Dental Emergency Room at the Baby-Clinic at the State University of Londrina (UEL) referred from the Basic Health Unit accompanied by her mother. The complaint was a "ball under the tongue" with a duration of approximately 3 months. Mother reported no history of trauma/bite and/or recurrence episodes. The child reported discomfort in eating and talking but without the presence of pain.

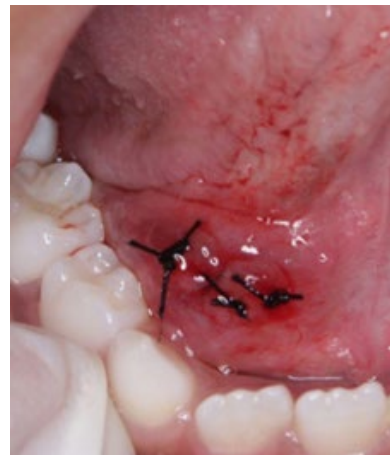During the intraoral examination, a reddish bulla of approximately 1.5 cm in diameter located on the right side of the buccal floor in the form of a dome, smooth surface, sessile base, regular contour and fluctuating consistency on palpation was noted (Figure 1). Based on the clinical aspects and the current history of the lesion, the diagnosis was OR.

Among the possible therapeutic procedures, the micromarsupialization

technique was chosen. For legal reasons, the mother's consent was initially obtained and explanations of the procedure to be performed for the child. The entire oral surgical procedure was performed on an outpatient basis. The preoperative period began with the patient rinsing with an antiseptic solution of 0.12% chlorhexidine digluconate (Perioplak, Reymer, Aparecida de Goiânia-GO, Brazil) for approximately one minute. Subsequently, a topical anesthetic based on 20% benzocaine (DFL, Rio de Janeiro-RJ, Brazil) was applied to the lesion for two minutes. Afterward, interrupted sutures with 4.0 silk thread (Silk-Brasil) were passed superficially towards the largest diameter of the dome of the lesion. Atraumatic needle was used to avoid tissue tears. After transfixation, a "to-and-fro" movement was performed and the suture was manipulated in and out of the lesion to ensure establishment of effective drainage channels. The surgical knot was not too tight to avoid necrosis, and gentle compression of the lesion was performed to remove the mucus (Figure 2). Finally, the child and the guardian received postoperative instructions on diet, toothbrushing with 5 ml of chlorhexidine digluconate 0.12% twice a day for seven days.

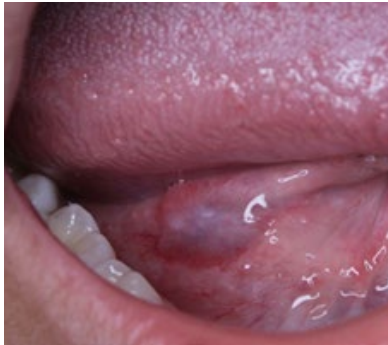

**Figure 1.** Preoperative clinical aspect showing presence of ranula on the right floor of the mouth.

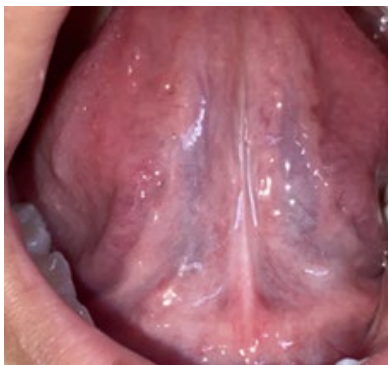

**Figure 2.** Clinical aspect of lesion after micromarsupialization.

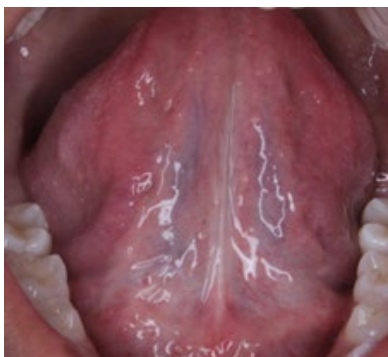After 7 days, the lesion regressed and the suture was removed (Figure 3). In clinical follow-ups of 30 days (Figure 4) and 8 months (Figure 5), no clinical signs of recurrence were observed.



**Figure 3.** 1-week postoperative after suture removal.



**Figure 4.** No signs of inflammation of the oral mucosa after 30 days of follow-up.

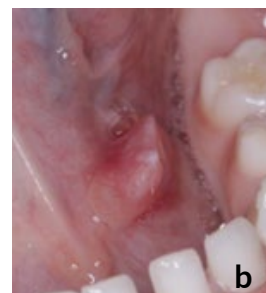
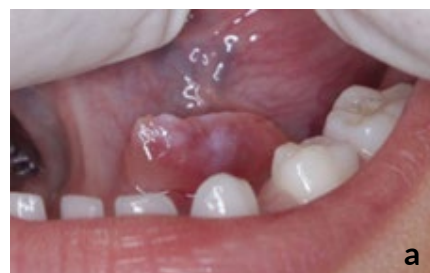
**Figure 5.** No signs of inflammation of the oral mucosa after 8 months of follow-up.

## Case 2

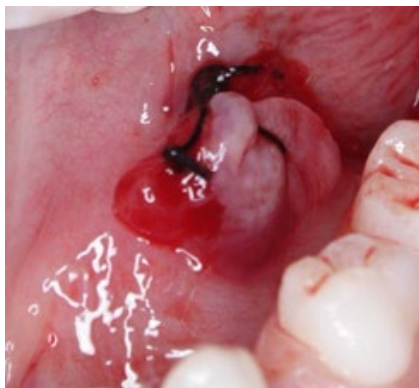A 5-year-old girl, melanoderma, diagnosed with Attention Deficit Disorder with Hyperactivity, attended the Pediatric Dental Emergency Room at the Baby-Clinic at the State University of Londrina (UEL) referred from the Basic Health Unit accompanied by her parents. The complaint was a “bubble on the tongue” lasting approximately 2 months. Parents did not report trauma/bite history and/or recurrence episodes. The child did not report painful symptoms or discomfort when eating.

On intraoral examination, a bulla of pinkish color equal to the mucosa of approximately 1 cm in diameter located on the left side of the buccal floor in the circumscribed shape, smooth surface, sessile base, regular contour and fluctuating consistency on palpation was noted (Figures 6a and b).



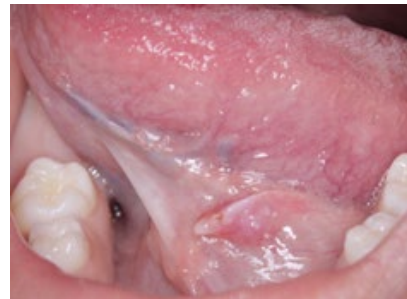**Figures 6 a y 6b.** Preoperative clinical aspect showing presence of ranula on the left floor of the mouth.

After obtaining legal parental consent, the surgical procedure of choice was micromarsupialization. The entire oral surgical procedure was performed on an outpatient basis. The preoperative period began with the patient rinsing with an antiseptic solution of 0.12% chlorhexidine digluconate (Perioplak, Reymer, Aparecida de Goiânia-GO, Brazil) for approximately one minute. Subsequently, a topical anesthetic based on 20% benzocaine (DFL, Rio de Janeiro-RJ, Brazil) was applied to the lesion for two minutes. Afterward, interrupted sutures with 4.0 silk thread (Silk-Brasil) were passed superficially towards the largest diameter of the dome of the lesion. Atraumatic needle was used to avoid tissue tears. After transfixation, a "to-and-fro" movement was performed and the suture was manipulated in and out of the lesion to ensure establishment of effective drainage channels. The surgical knot was not too tight to avoid necrosis, and gentle compression of the lesion was performed to remove the mucus (Figure 7). Finally, the child and the guardian received postoperative instructions on diet, toothbrushing with 5 ml of chlorhexidine digluconate 0.12% twice a day for seven days.

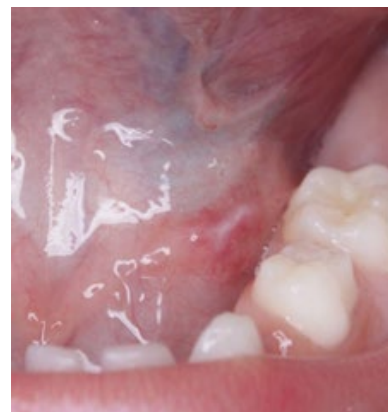

**Figure 7.** Clinical aspect of lesion after micromarsupialization.

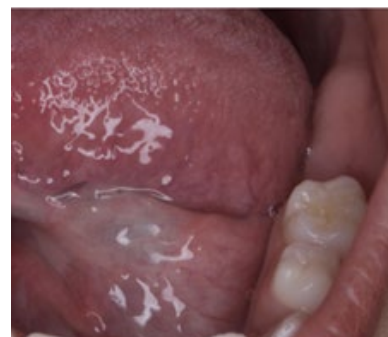After 7 days, the lesion regressed and the suture was removed (Figure 8). In the 15-day clinical follow-up (Figure 9) partial regression of the lesion was observed, with 1 month total regression and 6 months (Figure 10), no clinical signs of recurrence were observed.



**Figure 8.** 1-week postoperative after suture removal.



**Figure 9.** No signs of inflammation of the oral mucosa after 15 days of follow-up



**Figure 10.** No signs of inflammation of the oral mucosa after 6 months of follow-up

## Discussion

Ranulas, a subset of mucoceles, which occur on the floor of the mouth, are pseudocysts resulting from extravasation of mucin into the surrounding soft tissues after rupture or obstruction of one or more excretory ducts of the sublingual gland.<sup>1-3</sup> The clinical term “ranula” is derived from the Latin word “rana” (meaning frog) because the shape of the lesion is similar to the translucent underbelly of the animal.<sup>5,6</sup>

Regarding clinical features, OR are characteristically large and appear as a tense fluctuant dome-shaped vesicle, sometimes with a blue hue or pinkish color similar to that of the mucosa. Lesions located more deeply have pinkish colors while superficial lesions have translucent or bluish colors. The most common site is the lateral floor of the oral cavity.<sup>5</sup> OR usually occurs in the first or second decade of life<sup>3,5,6,9</sup>, and more frequently in females at a proportion of 1:1.4.<sup>8,9</sup> In both reported cases, the patients were children in their first decade of life and female, with the presence of the lesion located laterally to the midline of the floor of the mouth.

OR can be treated by surgical excision, sclerotherapy<sup>4,11</sup>, cryotherapy, LASER ablation<sup>3,11</sup>, hydro-dissection<sup>11</sup>, marsupialization and micromarsupialization.<sup>3,4,11</sup> Regardless of invasive or conservative treatment, it is important to reach the muscle layer during treatment.<sup>12</sup> Then, treatments are not always tolerated by the children or their parents.<sup>13</sup>

The micromarsupialization technique was recommended by Cardoso<sup>14</sup>, who obtained good results in the treatment of mucoceles. In

2001, Delbem *et al.*<sup>15</sup> used a single 4.0 suture with a permanence time of 7 days.<sup>15</sup> Sandrini *et al.* suggested an increase in the number of sutures which should be maintained for 30 days after micromarsupialization. This modification aims to form several new permanently epithelialized tracts along the path of the performed sutures.<sup>16</sup> However, future studies have shown difficulty in maintaining the suture for long periods due to the possibility of discomfort and the emergence of secondary infections as a result of compromised oral hygiene in pediatric patients.<sup>13,17,18</sup> Thus, maintaining the sutures for 7 days, as in the reported cases, is sufficient for lesion regression during this period.<sup>13,17,18</sup>

Micromarsupialization is particularly recommended for pediatric patients or adults with disabilities. It is worth mentioning that the micromarsupialization technique does not allow biopsy and the diagnosis remains exclusively clinical.<sup>13</sup> Given this, clinical discernment is essential for the application of the technique in benign lesions that demonstrate the potential for total regression.

Regarding the recurrence rate, there is no consensus in the literature. Some authors claim that conservative treatments such as micromarsupialization have high recurrence rates<sup>16,19</sup>, which can reach 43%.<sup>16</sup> Nonetheless, several studies have shown potential for total regression of 80% to 87.5% of cases with the micromarsupialization technique.<sup>4,13,17</sup> Therefore, it is clear that the micromarsupialization technique in children is an effective procedure and, as well as any other procedure, requires longitudinal clinical follow-up to reduce the risk of recurrence.

## Conclusion

Based on the reported clinical cases, the use of the micromarsupialization technique refers to an effective surgical procedure for the treatment of oral ranulas in pediatric dentistry. The use of this technique in pediatric patients proved to be simple, low cost, conservative, well tolerated by children and capable of being performed in an outpatient setting.

Micromarsupialization is another relevant treatment option for oral ranulas, as it represents a simple, less invasive therapeutic alternative that did not present surgical complications and/or recurrences in clinical follow-up.

## Conflict of Interest

The authors declare that there are no conflicts of interest regarding the publication of this paper.

## Ethics Statement

The authors declare that the parents gave consent for images and clinical information of the case to be reported in scientific publications. Parents understand that the child's name and initials will not be published and efforts will be made to conceal the child's identity. This article complies with the protocols of the Research Ethics Committee of the State of University of Londrina.

## References

1. Huzaifa M, Soni A. Mucocele and Ranula. 2023 Jul 24. In: StatPearls [Internet]. Treasure Island (FL): StatPearls Publishing; 2023 Jan-. PMID: 32809690.
2. Lin YH, Kao CH. Synchronous contralateral oral and cervical ranula. *Otolaryngol Head Neck Surg.* 2001 Oct;125(4):420-1. doi: 10.1067/mhn.2001.115523. PMID: 11593187.
3. O'Connor R, McGurk M. The plunging ranula: diagnostic difficulties and a less invasive approach to treatment. *Int J Oral Maxillofac Surg.* 2013 Nov;42(11):1469-74. doi: 10.1016/j.ijom.2013.03.019. Epub 2013 May 29. PMID: 23726274.
4. Patel MR, Deal AM, Shockley WW. Oral and plunging ranulas: What is the most effective treatment? *Laryngoscope.* 2009 Aug;119(8):1501-9. doi: 10.1002/lary.20291. PMID: 19504549; PMCID: PMC4455536.
5. Gupta A, Karjodkar FR. Plunging ranula: a case report. *ISRN Dent.* 2011;2011:806928. doi: 10.5402/2011/806928. Epub 2010 Sep 8. PMID: 21991487; PMCID: PMC3169347.
6. Baurmash HD. Mucoceles and ranulas. *J Oral Maxillofac Surg.* 2003 Mar;61(3):369-78. doi: 10.1053/joms.2003.50074. PMID: 12618979.
7. Yuca K, Bayram I, Cankaya H, Caksen H, Kiroğlu AF, Kiriş M. Pediatric intraoral ranulas: an analysis of nine cases. *Tohoku J Exp Med.* 2005 Feb;205(2):151-5. doi: 10.1620/tjem.205.151. PMID: 15673973.
8. Packiri S, Gurunathan D, Selvarasu K. Management of Paediatric Oral Ranula: A Systematic Review. *J Clin Diagn Res.* 2017 Sep;11(9):ZE06-ZE09. doi: 10.7860/JCDR/2017/28498.10622. Epub 2017 Sep 1. PMID: 29207849; PMCID: PMC5713871.
9. Bachesk AB, Bin LR, Iwaki IV, Iwaki Filho L. Ranula in children: Retrospective study of 25 years and literature review of the plunging variable. *Int J Pediatr Otorhinolaryngol.* 2021 Sep;148:110810. doi: 10.1016/j.ijporl.2021.110810. Epub 2021 Jun 23. PMID: 34242981.
10. Neville BW, Damm DD, Allen CM, Chi AC. Patologia de glândulas salivares. In: *Patologia Oral e Maxilofacial.* Rio de Janeiro: Ed. Elsevier, 2009. p. 455-474.

11. Kokong D, Iduh A, Chukwu I, Mugu J, Nuhu S, Augustine S. Ranula: Current Concept of Pathophysiologic Basis and Surgical Management Options. *World J Surg.* 2017 Jun;41(6):1476-1481. doi: 10.1007/s00268-017-3901-2. PMID: 28194490; PMCID: PMC5422487.
12. Huang IY, Chen CM, Kao YH, Worthington P. Treatment of mucocele of the lower lip with carbon dioxide laser. *J Oral Maxillofac Surg.* 2007 May;65(5):855-8. doi: 10.1016/j.joms.2006.11.013. PMID: 17448832.
13. Piazzetta CM, Torres-Pereira C, Amenábar JM. Micro-marsupialization as an alternative treatment for mucocele in pediatric dentistry. *Int J Paediatr Dent.* 2012 Sep;22(5):318-23. doi: 10.1111/j.1365-263X.2011.01198.x. Epub 2011 Nov 17. PMID: 22092694.
14. Tommasi AF: Doenças das glândulas salivares. In *Diagnóstico em patologia bucal*, 1st Ed. São Paulo: Artes Médicas, 1982, pp 303-26.
15. Delbem ACB, Cunha, RF, Vieira, AEM, Ribeiro, LLG. Treatment of salivary retention phenomena in children using the micromarsupialization technique. *Revista da APCD.* 2001;55(1):51-54.
16. Sandrini FA, Sant'ana-Filho M, Rados PV. Ranula management: suggested modifications in the micromarsupialization technique. *J Oral Maxillofac Surg.* 2007 Jul;65(7):1436-8. doi: 10.1016/j.joms.2006.06.291. PMID: 17577520.
17. Sagari SK, Vamsi KC, Shah D, Singh V, Patil GB, Saawarn S. Micro-marsupialization: a minimally invasive technique for mucocele in children and adolescents. *J Indian Soc Pedod Prev Dent.* 2012 Jul-Sep;30(3):188-91. doi: 10.4103/0970-4388.105008. PMID: 23263419.
18. Giraddi GB, Saifi AM. Micro-marsupialization versus surgical excision for the treatment of mucoceles. *Ann Maxillofac Surg.* 2016 Jul-Dec;6(2):204-209. doi: 10.4103/2231-0746.200324. PMID: 28299258; PMCID: PMC5343628.
19. Nguyen BN, Malone BN, Sidman JD, Barnett Roby B. Excision of sublingual gland as treatment for ranulas in pediatric patients. *Int J Pediatr Otorhinolaryngol.* 2017 Jun;97:154-156. doi: 10.1016/j.ijporl.2017.04.003. Epub 2017 Apr 5. PMID: 28483227.

---

Recibido: 19/4/23

Aceptado: 24/8/23

Correspondence: Lucas Fernando Oliveira Tomáz Ferraresso, correo: lucas.fernando@uel.br